

Light and electron microscopy of *Myxobolus sciades* n. sp. (Myxozoa), a parasite of the gills of the Brazilian fish *Sciades herzbergii* (Block, 1794) (Teleostei: Ariidae)

Carlos Azevedo^{1,2/+}, Graça Casal^{1,3}, Ivete Mendonça⁴, Erisson Carvalho⁴, Patrícia Matos⁵, Edilson Matos⁶

¹Departamento de Biologia Celular, Instituto de Ciências Biomédicas Abel Salazar, Centro Interdisciplinar de Investigação Marinha e Ambiental, Universidade do Porto, Largo Prof. Abel Salazar 2, 4099-003 Porto, Portugal ²King Saud University, Riyadh, Saudi Arabia ³Departamento de Ciências, Instituto Superior de Ciências da Saúde Norte, Cooperativa de Ensino Superior, Politécnico e Universitário, Gandra, Portugal ⁴Departamento de Veterinária, Laboratório de Sanidade Animal, Universidade Federal do Piauí, Teresina, PI, Brasil ⁵Laboratório de Animais Aquáticos, Universidade Federal do Pará, Belém, PA, Brasil ⁶Laboratório de Pesquisa Carlos Azevedo, Universidade Federal Rural da Amazônia, Belém, PA, Brasil

A myxosporean parasite in the gill lamellae of the freshwater teleost fish, Sciades herzbergii (Ariidae) (Block, 1794), from the Poti River (Northeast of Brazil) was described by light and electron microscopy studies. Polysporic histozoic cyst-like plasmodia containing several life-cycle stages, including mature spores, were observed. The spores were pyriform and uninucleate, measuring $9.15 \pm 0.39 \mu\text{m}$ ($n = 50$) long, $4.36 \pm 0.23 \mu\text{m}$ ($n = 25$) wide and $2.61 \pm 0.31 \mu\text{m}$ ($n = 25$) thick. Elongated pyriform polar capsules (PC) were of equal size ($4.44 \pm 0.41 \mu\text{m}$ long and $1.41 \pm 0.42 \mu\text{m}$ in diameter) and each contained a polar filament with 9-10 coils obliquely arranged in relation to the axis of PC. The PC wall was composed of two layers of different electron densities. Histological analysis revealed the close contact of the cyst-like plasmodia with the basal portion of the epithelial gill layer, which exhibited some alterations in the capillary vessels. Based on the morphological and ultrastructural differences, the similarity of the spore features to those of the genus Myxobolus and the specificity of this host to previously described species, we describe a new species named Myxobolus sciades n. sp. in this study.

Key words: ultrastructure - parasite - Myxosporia - *Myxobolus sciades* n. sp. - gill - Brazilian fish

The genus *Myxobolus* (Bütschli, 1882) (family Myxobolidae) is one of the largest myxosporean groups and its members are important pathogens of freshwater and marine fish in several geographical areas (Eiras et al. 2005b, Lom & Dyková 2006). In a recent synopsis, 744 *Myxobolus* species have been identified parasitizing fish (Eiras et al. 2005b) and more recently, 792 named species of the same genus, including seven infecting amphibians, have been described (Lom & Dyková 2006). However, this number has been successively increasing over the years by the continuing description of new species in different countries, including Brazil (Casal et al. 2006, Martins & Onaka 2006, Eiras et al. 2007, Adriano et al. 2009a, b, Azevedo et al. 2009).

Most of the Brazilian *Myxobolus* species have been described based on only light microscopy descriptions and diagrammatic drawings (Walliker 1969, Kent & Hoffman 1984, Molnár & Békési 1993, Gioia & Cordeiro 1996, Molnár et al. 1998, Adriano et al. 2002, Cellere et al. 2002, Eiras et al. 2005a, 2007, Martins & Onaka 2006); even fewer have been described using light and ultrastructural observations (Casal et al. 1996, 2002, 2006, Azevedo et al. 2002, 2009, Tajdari et al. 2005, Adriano

et al. 2009a) as well as molecular analyses (Adriano et al. 2009b). However, some specific aspects of the histopathology have been simultaneously reported by invasion of different organs; *Myxobolus* spp most frequently infects the gills of fish (Molnár & Békési 1993, Molnár 2002, Eiras et al. 2005a, Casal et al. 2006, Lom & Dyková 2006, Adriano et al. 2009a, Azevedo et al. 2009).

In this paper, we describe light and ultrastructural data for a new myxosporidian species found in the gill of the teleost fish, *Sciades herzbergii*, which was collected from a river Northeast of Brazil.

MATERIALS AND METHODS

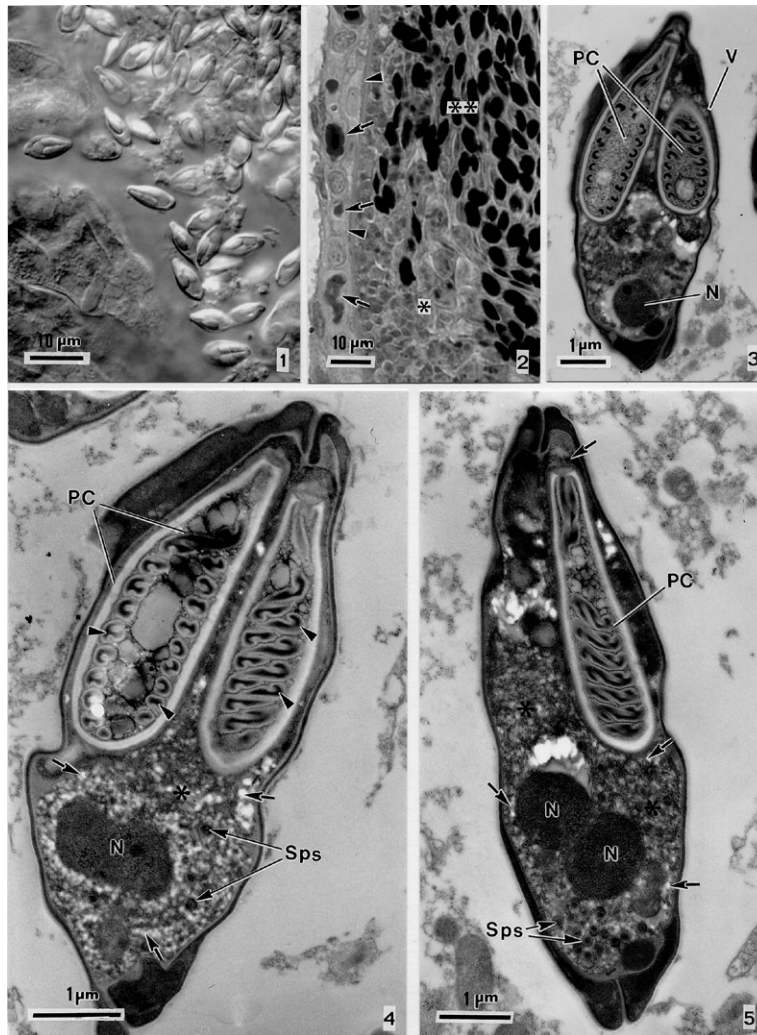
A parasite found in the secondary gill lamellae of the freshwater teleost fish, *S. herzbergii* (Block, 1794) (family Ariidae) (Brazilian common name *mandi*), was studied. Ten specimens were collected from June-August of 2009 in the Poti River (05°05'S 42°48'W) near the city of Teresina [state of Piauí (PI)] northeast of Brazil. The fish were lightly anaesthetised with MS 222 (Sandoz Laboratories) and dissected. Cyst-like plasmodia with numerous mature spores located in the basal insertions of the gill lamellae were examined and measured in fresh mounts with a light microscope equipped with Nomarski differential interference contrast (DIC) optics. For transmission electron microscopy (TEM), small, parasitised fragments of the infected gills were fixed in 3% glutaraldehyde in 0.2 M sodium cacodylate buffer (pH = 7.2) at 4°C for 10 h, washed overnight at 4°C with the same buffer and post-fixed in 2% OsO₄ buffered with the same solution for 3 h at 4°C. The fragments were

Financial support: Eng. António de Almeida Foundation (Porto, Portugal), CNPq, CAPES

+ Corresponding author: azevedoc@icbas.up.pt

Received 22 October 2009

Accepted 27 January 2010



Figs 1-5: *Myxobolus sciades* n. sp. parasite of the freshwater Brazilian fish *Sciades herzbergii*. 1: free fresh spores released from cyst-like plasmodia observed in differential interference contrast; 2: semi-thin section showing the periphery of cyst-like plasmodia in close contact with the epithelial gill cells (arrowheads) in which some aspects of compressed capillaries (arrows) were observed. Internally some developmental stages, immature spores (*) and mature spores (**), sectioned at different levels are randomly distributed throughout the cyst-like plasmodium; 3: spore sectioned longitudinally showing the valves (V), the two polar capsules (PC) and one of the two nuclei (N); 4: ultrastructural details of a spore sectioned longitudinally showing the organization of the PC and the arrangements of the polar filaments (arrowheads). The sporoplasm (*) shows the N surrounded by an extensive system of rough endoplasmic reticulum containing several vesicles and cisternae (arrows) and some sporoplasmosomes (Sps); 5: longitudinal section (lateral view) showing PCs and sporoplasm with the two Ns and some Sps both surrounded by the endoplasmic reticulum containing several vesicles and cisternae (arrows).

dehydrated in an ascending ethanol series with propylene oxide and embedded in Epon. Blocs were cut and semi-thin sections were stained with methylene blue and photographed under a light microscope (DIC). Ultrathin sections were double stained with aqueous uranyl acetate and lead citrate and then observed under a JEOL 100CXII TEM operated at 60 kV.

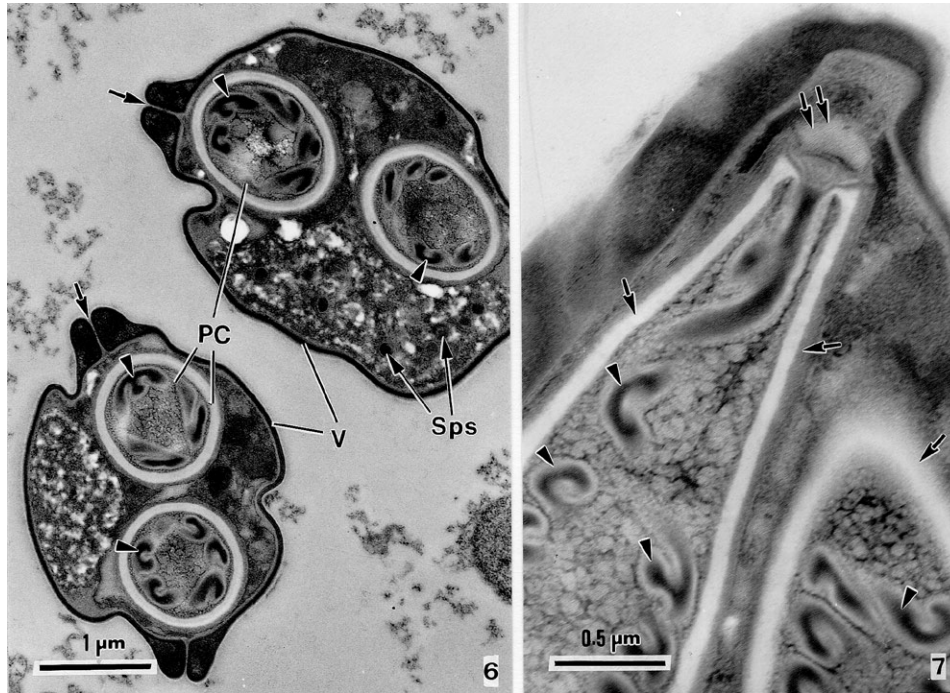
RESULTS

We observed several cyst-like plasmodia, with diam-

myxosporidian belonging to the genus *Myxozoa* (Bütschli, 1882) (Figs 1, 2). The infected gill had cellular and nuclear hypertrophy that was accompanied by morphological changes, such as organelle disorganisation and cytoplasm vacuolisation (Fig. 2).

We propose the establishment of a new species based on the morphology and ultrastructure results obtained for host specificity and the comparison with spores from previously described species.

Following Lom and Dyková (2006), this new species is classified as follows: Phylum *Myxozoa* (Grassé, 1970); Class *Myxosporea* (Bütschli, 1881); Order *Bivalvulida* (Schulman, 1959); Family *Myxobolidae* (Thélohan, 1892); Genus *Myxobolus* (Bütschli, 1882).



Figs 6, 7: *Myxobolus sciades* n. sp. parasite of the freshwater Brazilian fish *Sciades herzbergii*. 6: two spores sectioned transversally showing the valves (V) and their suture lines (arrows), polar capsules (PC), different sections of the polar filaments (arrowheads) and some sporoplasmosomes (Sps); 7: detail of the apical region of the PCs showing the PC wall (arrows) composed of two layers and the apical stopper (double arrows) and the different sections of the polar filament (arrowheads).

Myxobolus sciades n. sp.
(Figs 1-8)

Description - vegetative stages - White, ellipsoidal to spherical-shaped polysporic histozoic cyst-like plasmodia containing numerous mature spores (Figs 1, 2), in the secondary gill lamellae of the fish, *S. herzbergii*. The fresh mature spores had a pyriform shape, tapering anteriorly to a slight knob-like end (Figs 1, 2). The spore wall was thin (~62 nm thick) and smooth, comprising two equally-sized valves joined by a sutural ridge that is slightly oblique in relation to the spore axis (Figs 3-5). No mucus envelope was observed at the surface of the spore. Internally, two polar capsules (PCs) with an elongated pyriform shape and equal size, (Figs 3-7). The PCs occupied approximately two-thirds of the total spore length (Figs 3, 4). The apical portion of the PCs contained a developed stopper in close contact with the valves (Figs 4, 5, 7, 8). At the posterior pole of the spore, a sporoplasm contained two spherical sporoplasmosomes, glycogen granules and an extensive system of rough endoplasmic reticulum with vesicles and cisternae (Figs 4, 5).

Type host - Teleost fish *S. herzbergii* (Block, 1794) (family Ariidae) (14-22 cm in length, on average).

Site of infection - Cyst-like plasmodia containing spores were located in the bases of the secondary gill lamellae.

Prevalence of infection - Six out of 10 (2/4 males and 4/6 females) adult fish (60%) were parasitised.

Type locality - Poti River (05°05'S 42°48'W), near the city of Teresina (PI), Brazil.

Type data and depository - A glass slide containing semi-thin sections of mature spores and some other developmental stages of the hapantotype was deposited in the International Protozoan Type Slides Collection at the Smithsonian Institution, Washington DC 20560, USA under acquisition USNM # 1134556.

Etymology - The specific epithet name (*sciades*) derives from the generic name of the host species.

Histopathology - Histopathological alterations in the surrounding region where the cyst-like plasmodia were located showed deformities of the gill lamellae and compression of the capillaries.

DISCUSSION

The spores obtained from the gill lamellae of the fish, *S. herzbergii*, revealed morphological and ultrastructural characteristics similar to those previously described for the genus *Myxobolus* (Bütschli, 1882) (Lom & Dyková 1992, 2006). In the present paper, we describe a new his-

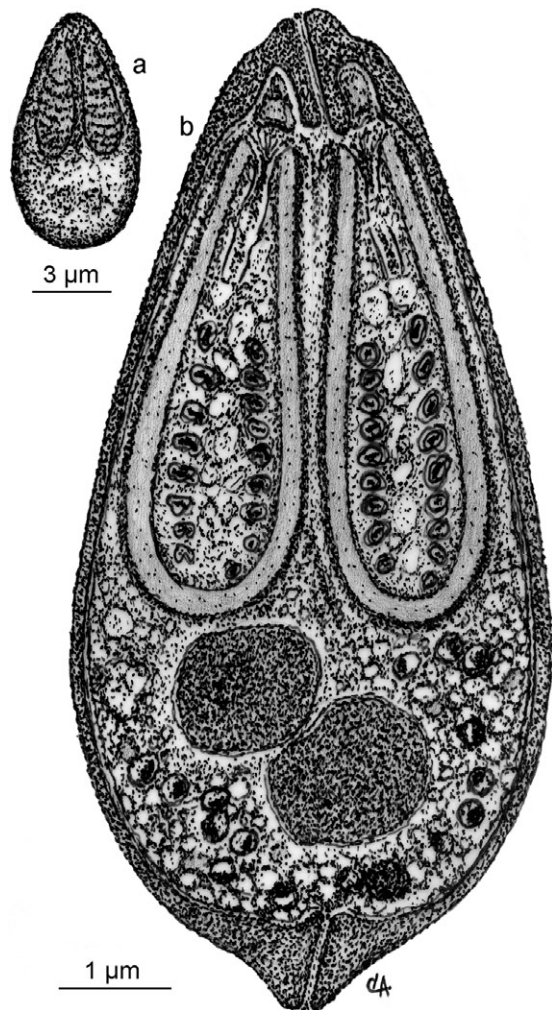


Fig. 8: *Myxobolus sciades* n. sp. parasite of the freshwater Brazilian fish *Sciades herzbergii*. Schematic drawings of a valvar view of the spore morphology, as observed in differential interference contrast (a) and in longitudinal ultra-thin section in transmission electron microscopy (b).

tozoic species found in the gill lamellae, which is frequently the preferential site for the development of fish myxosporeans (Molnár 2002). Unfortunately, studies of several *Myxobolus* species reported to infect the same organ make few references to the ultrastructural morphology of the spores and the plasmodia (Lom & Dyková 1992). Additionally, most of the early species descriptions are vague, with few light micrographs and line drawings of the spores. Until now, only 27 *Myxobolus* species have been reported from South America, of which 24 valid species were described in Brazilian fish. When comparing the present results with those for the different *Myxobolus* spp previously described in Brazilian fish (Table), we observed several morphological differences in the dimensions and shape of the spores and PCs as well as the number, position and organisation of the coils in the PFCs. Species such as *Myxobolus inaequus* (Kent & Hoffman 1984), *Myxobolus desaequalis* (Azevedo et al. 2002) and *Myxobolus absonus* (Cellere et al. 2002) were excluded from the possibility of belonging to the same species, because these organisms possess two unequally-sized PCs. Reported species infecting organs other than the gills were also excluded from the comparative table.

Of the 24 species present in Brazilian fish, only nine can be carriers of *Myxobolus* spp because this species has equal-sized PCs and infects freshwater fish gills (Table). The spores of *M. sciades* n. sp. described herein are smaller (in length, width and thickness) than the species referred to in Table (except the *Myxobolus condrophilus* spores, which are much smaller). Furthermore, the number of PFCs described has 9-10 coils, whereas all PFCs described in the different species have fewer coils (except for *Myxobolus braziliensis*, which has a similar number). However, *M. braziliensis* has a different ultrastructural organisation of the PFCs, which is evident in the apical region of the PCs, compared to *M. sciades* n. sp., which contains a complex apical stopper that is in close contact with the spore wall.

TABLE

Eq o rctcwxg" o gcuwtg o gpvu" *kp" o + "qh" v" jg" urqtgu" y kvj " gswcn/uk | gf" rqnct" ecruwngu" htq o " *Myxobolus* spp parasitizing gills of the Brazilian freshwater fish

<i>Myxobolus</i> spp	Sp L	Sp W	Sp T	PC L	PC W	PF C	Ct / Pm	References
<i>Myxobolus condrophilus</i>	6	4.5	3.5	3	-	-	-	Nemeczek (1926)
<i>Myxobolus noguchii</i>	13.6	8.5	-	6.8	2.2	-	-	Pinto (1928)
<i>Myxobolus colossomatis</i>	11.8	6.9	-	6.0	2.1	7-8	-	Molnár and Békési (1993)
<i>Myxobolus braziliensis</i>	10.2	5.2	3.7	5.3	1.4	9-11	300	Casal et al. (1996)
<i>Myxobolus insignis</i>	14.5	11.3	7.8	7.6	4.2	6	20-80	Eiras et al. (2005a)
<i>Myxobolus peculiaris</i>	25.2	15.4	-	10.7	4.4	4-5	-	Martins and Onaka (2006)
<i>Myxobolus cordeiroi</i>	~11	~7.3	-	~5.4	~1.5	5-6	~2000	Adriano et al. (2009a)
<i>Myxobolus salminus</i>	10.1	6.1	5.0	4.6	1.7	7-8	~100	Adriano et al. (2009b)
<i>Myxobolus heckelli</i>	12.7	6.6	4.0	2.9	1.7	4-5	~250	Azevedo et al. (2009)
<i>Myxobolus sciades</i> n. sp.	9.15	4.36	2.61	4.44	1.63	9-10	60	Present study

Ct/Pm: cysts/plasmodia; PC L: polar capsule length; PC W: polar capsules width; PF C: polar filament coils; Sp L: spore length; Sp T: spore thick; Sp W: spore width.

Comparison of our results with other *Myxobolus* species that infect the gills of Brazilian freshwater fish (Table) revealed significant differences in morphometric characters (size and body shape) of the spores, ultrastructural organisation of the PCs and their PFCs and host specificity. However, when comparing other international *Myxobolus* species that infect the gill tissues of freshwater fish (Eiras et al. 2005b) to those described herein, we observed that spores with a similar shape and size have several morphological differences in both length and width of PC as well as their position in relation to the PC axis. This analysis suggests that the presently described parasite is different from other *Myxobolus* spp and therefore, *M. sciades* is a new species.

The pathology associated with gill infection by *M. sciades* n. sp. was similar to that observed in other Brazilian *Myxobolus* spp described previously (Molnár et al. 1998, Tajdari et al. 2005, Adriano et al. 2009a, b, Azevedo et al. 2009). The compression of the surrounding capillaries seems to indicate that this parasite has pathogenic activity.

ACKNOWLEDGMENTS

To the iconographic work of J Carvalho and to the anonymous reviewers, for their most helpful comments and suggestions.

REFERENCES

- Adriano EA, Arana S, Alves AL, Silva MRM, Ceccarelli PS, Henrique-Silva F, Maia AAM 2009a. *Myxobolus cordeiroi* n. sp., a parasite of *Zungaro jahu* (Siluriformes: Pimelodiade) from Brazilian Pantanal: morphology, phylogeny and histopathology. *Vet Parasitol* 162: 221-229.
- Adriano EA, Arana S, Carriero MM, Naldoni J, Ceccarelli PS, Maia AAM 2009b. Light, electron microscopy and histopathology of *Myxobolus salminus* n. sp., a parasite of *Salminus brasiliensis* from the Brazilian Pantanal. *Vet Parasitol* 165: 25-29.
- Adriano EA, Arana S, Ceccarelli PS, Cordeiro NS 2002. Light and scanning microscopy of *Myxobolus porofilus* sp. n. (Myxosporea: Myxobolidae) infecting the visceral cavity of *Prochilodus lineatus* (Pisces: Characiformes: Prochilodontidae) cultivated in Brazil. *Folia Parasitol* 49: 259-262.
- Azevedo C, Casal G, Matos P, Ferreira I, Matos E 2009. Light and electron microscopy of the spore of *Myxobolus heckelii* n. sp. (Myxozoa), parasite from the Brazilian fish *Centromochlus heckelii* (Teleostei: Auchenipteridae). *J Eukaryot Microbiol* 56: 589-593.
- Azevedo C, Corral L, Matos E 2002. *Myxobolus desaequalis* n. sp. (Myxozoa: Myxosporea), parasite of the Amazonian freshwater fish, *Aptereronotus albifrons* (Teleostei: Aptereronotidae). *J Eukaryot Microbiol* 49: 485-488.
- Casal G, Matos E, Azevedo C 1996. Ultrastructural data on the life cycle stages of *Myxobolus braziliensis* n. sp. parasite of an Amazonian fish. *Europ J Protistol* 32: 123-127.
- Casal G, Matos E, Azevedo C 2002. Ultrastructural data on the spore of *Myxobolus maculatus* n. sp. (phylum Myxozoa), parasite from the Amazonian fish *Metynniss maculatus* (Teleostei). *Dis Aquat Org* 51: 107-112.
- Casal G, Matos E, Azevedo C 2006. A new myxozoan parasite from the Amazonian fish *Metynniss argenteus* (Teleostei: Characidae): light and electron microscope observations. *J Parasitol* 92: 817-821.
- Cellere EF, Cordeiro NS, Adriano EA 2002. *Myxobolus absonus* sp. n. (Myxozoa: Myxosporea) parasitizing *Pimelodus maculatus* (Siluriformes: Pimelodidae), a South American freshwater fish. *Mem Inst Oswaldo Cruz* 97: 79-80.
- Eiras JC, Abreu PC, Robaldo R, Pereira-Junior J 2007. *Myxobolus platanus* n. sp. (Myxosporea: Myxobolidae), a parasite of *Mugil platanus* Günther, 1880 (Osteichthyes: Mugilidae) from Lagoa dos Patos, RS, Brazil. *Arq Bras Med Vet Zootec* 59: 895-898.
- Eiras JC, Malta JCO, Varella AMB, Pavanelli GC 2005a. *Myxobolus insignis* sp. n. (Myxozoa, Myxosporea, Myxobolidae), a parasite of the Amazonian teleost fish *Semaprochilodus insignis* (Osteichthyes: Prochilodontidae). *Mem Inst Oswaldo Cruz* 100: 245-247.
- Eiras JC, Molnár K, Lu YS 2005b. Synopsis of the species of *Myxobolus* Bütschli, 1882 (Myxozoa: Myxosporea: Myxobolidae). *Syst Parasitol* 61: 1-46.
- Gioia I, Cordeiro NS 1996. Brazilian myxosporidians' check-list (Myxozoa). *Acta Protozool* 35: 137-149.
- Kent ML, Hoffman GL 1984. Two new species of Myxozoa, *Myxobolus inaequus* sp. n. and *Henneguya theca* sp. n. from the brain of a South American knife fish, *Eigemannia virescens* (V.). *J Protozool* 31: 91-94.
- Lom J, Dyková I 1992. Myxosporidia (Phylum Myxozoa). 7. Protozoan parasites of fishes. Developments in aquaculture and fisheries science. *Dev Aquat Fish Sci* 26: 159-235.
- Lom J, Dyková I 2006. Myxozoa genera: definition and notes on taxonomy, life-cycle terminology and pathogenic species. *Folia Parasitol* 53: 1-36.
- Martins ML, Onaka EM 2006. *Henneguya garavelli* n. sp. and *Myxobolus peculiaris* n. sp. (Myxozoa: Myxobolidae) in the gills of *Cyphocharax nagelli* (Osteichthyes: Curimatidae) from Rio do Peixe Reservoir, São José do Rio Pardo, São Paulo, Brazil. *Vet Parasitol* 137: 253-261.
- Molnár K 2002. Site preference of fish myxosporeans in the gill. *Dis Aquat Org* 48: 197-207.
- Molnár K, Békési L 1993. Description of a new *Myxobolus* species, *M. colossomatis* n. sp. from the teleost *Colossoma macropomum* of the Amazon River basin. *J Appl Ichthyol* 9: 57-63.
- Molnár K, Ranzani-Paiva MJ, Eiras JC, Rodrigues EL 1998. *Myxobolus macroplasmodialis* n. sp. (Myxozoa: Myxosporea), a parasite of the abdominal cavity of the characid teleost, *Salminus maxillosus* in Brazil. *Acta Protozool* 37: 241-245.
- Nemeczek A 1926. Beiträge zur Kenntnis der Myxosporidienfauna Brasiliens. *Arch Protistenk* 22: 143-149.
- Pinto C 1928. *Myxobolus noguchii*, *M. stokesi* e *Henneguya iheringi*, espécies novas de myxosporídeos de peixes de água doce do Brasil. *Bol Biol* 12: 41-43.
- Tajdari J, Matos E, Mendonça I, Azevedo C 2005. Ultrastructural morphology of *Myxobolus testicularis* n. sp., parasite of the testis of *Hemiodopsis microlepis* (Teleostei: Hemiodontidae) from the NE of Brazil. *Acta Protozool* 44: 377-384.
- Walliker D 1969. Myxosporidea of some Brazilian freshwater fishes. *J Parasitol* 55: 942-948.