

## Chronic Experimental Infection by *Trypanosoma cruzi* in *Cebus apella* Monkeys

A Riarte<sup>o</sup>, A Sinagra, M Lauricella, N Bolomo\*, M Moreno, P Cossio\*\*/+ ,  
R Arana\*\*, EL Segura

Instituto Nacional de la Enfermedad de Chagas Dr Mario Fatała Chaben (Indiech), Avda Paseo Colón 560, 1063 Buenos Aires, Argentina \*Hospital Fernandez, Buenos Aires, Argentina \*\*Centro de Investigaciones Médicas (Cemic), Buenos Aires, Argentina

*Twenty young male Cebus apella monkeys were infected with CA1 Trypanosoma cruzi strain and reinfected with CA1 or Tulahuen T. cruzi strains, with different doses and parasite source. Subpatent parasitemia was usually demonstrated in acute and chronic phases. Patent parasitemia was evident in one monkey in the acute phase and in four of them in the chronic phase after re-inoculations with high doses of CA1 strain. Serological conversion was observed in all monkeys; titers were low, regardless of the methods used to investigate anti-T. cruzi specific antibodies. Higher titers were induced only when re-inoculations were performed with the virulent Tulahuén strain or high doses of CA1 strain. Clinical, electrocardiographic and ajmaline test evaluations did not reveal changes between infected and control monkeys. Histopathologically, cardiac lesions were always characterized by focal or multifocal mononuclear infiltrates and/or isolated fibrosis, as seen during the acute and chronic phases; neither amastigote nests nor active inflammation and fibrogenic processes characteristic of human acute and chronic myocarditis respectively, were observed. These morphological aspects more closely resemble those found in the "indeterminate phase" and contrast with the more diffuse and progressive pattern of the human chagasic chronic myocarditis. All monkeys survived and no mortality was observed.*

Key words: *Trypanosoma cruzi* - chronic infection - reinfection - monkeys - *Cebus apella* - animal models

Chagas' disease is an endemic parasitosis of several regions of the Americas. The disease has a high social impact, and high morbidity and mortality have been observed in patients with chronic *Trypanosoma cruzi* infection. Recently, it was estimated that 90 million people are at risk of *T. cruzi* infection in these areas with an overall prevalence of 16-18 million (WHO 1989), where 20-40% of them display electrocardiographic abnormalities (WHO 1960). The pathogenic processes of chronic Chagas' disease are not fully known due to the lack of a suitable animal model reproducing the disease. The difficulties in obtaining this model have also prevented the development of new chemotherapeutic and immunoprophylactic methods for the infection.

Non-human primates constitute a priority in studies of experimental Chagas' disease due to

their phylogenetic closeness to human beings and several studies have described chronic infection of Old and New World monkeys with *T. cruzi*. However, due to the lack of clear results regarding myocardial involvement observed in the different studies, the monkeys have not been considered the most suitable animal model for chronic Chagas' disease.

The CA1 is a non-lethal and myotropic strain that induces long lasting parasitemia and a poor immunogenic response in mice (González Cappa et al. 1980, Bijovsky et al. 1983, Sánchez & González Cappa 1983). This characteristic "low virulence" was the reason for selecting for infection two prepuberal *C. apella* monkeys which developed electrocardiographic abnormalities, myocardial fibrosis and megacolon (Bolomo et al. 1980). These promissory results encouraged the evaluation of the *Cebus* monkey as an animal model for Chagas' disease. In this work the usefulness of *C. apella* was investigated using a larger number of animals following the course of infection after inoculation and/or re-inoculations with several doses of CA1 and Tulahuén *T. cruzi* strains.

### MATERIALS AND METHODS

*Animals* - Thirty-two young male *C. apella* monkeys were obtained from the Argentine Cen-

This investigation received financial support from the UNDP/World Bank/WHO Special Programme for Research and Training in Tropical Diseases and the Ministerio de Salud y Acción Social de la República Argentina.

<sup>o</sup>Corresponding author

+Deceased in 1985

Received 20 October 1994

Accepted 12 July 1995

ter of Primates (Caprim, Corrientes, Argentina), with an average weight of 2.33 kg (1.8-2.8 kg). The animals were kept in an indoor colony (Ilaimus, University del Salvador) in individual cages with standard pelleted food (Cargill, Argentina) supplemented with fresh fruit and water *ad libitum*. *T. cruzi* infection of the monkeys was ruled out through serology and xenodiagnosis with *Triatoma infestans*, *T. guayana*, *T. sordida*, *T. rubrovaria* and *Rhodnius prolixus* as vectors species. They had normal electrocardiograms and clinical pictures.

**Parasite strains** - Metacyclic trypomastigotes (MT) from *T. infestans* and blood trypomastigotes (BT) from infected mice of the CA1 and Tulahuén *T. cruzi* strains were used. CA1 was isolated from a human chronic myocarditis (González Cappa et al. 1980) and Tulahuén strain from a triatoma bug (Pizzi & Prager 1952). Schedule of experimental infection with number of infected monkeys, *T. cruzi* strains, number and timing of inoculations and re-inoculations are shown in Table I. Twelve monkeys were sham inoculated and kept as controls.

**Evaluation of infection** - Infected and control monkeys were evaluated for parasitemia, serology and clinical signs every 10 days during the first 30 days following each inoculation, once a month until 90 days and every two months thereafter up to the end of the experiment, at 1200 days post infection (pi).

**Parasitological studies** - Parasites in blood were directly determined by the Strout concentration method (Strout 1962), and by indirect methods such as xenodiagnosis, hemoculture and blood

inoculation into nude mice. **Xenodiagnosis** - Forty *T. infestans* nymphs were fed directly on infected monkeys and the feces of each bug were pooled and examined at 30 and 60 days post-exposure (Cerisola et al. 1974). In addition, artificial xenodiagnosis was performed by feeding bugs with blood extracted from infected monkeys (Abramo Orrego et al. 1980). **Hemoculture** - Five hundred microliters of blood of infected monkeys were cultured in biphasic media (agar-blood-BHT) and observed every three weeks during four months (Abramo Orrego et al. 1980). **Inoculation into nude mice** - Five weanling N/NIH nude mice were inoculated with 0.2 ml of heparinized blood of each infected monkey and parasitemia was controlled twice a week during 40 days pi.

Strout and xenodiagnosis were done in a systematic way, while artificial xenodiagnosis, hemoculture and inoculation in nude mice were performed at 430 and 470 days pi to intensify the parasite search.

**Immunological studies** - The presence of anti-*T. cruzi* IgG was tested by ELISA (Voller et al. 1975), using epimastigotes as antigen (Ruiz et al. 1990) and immunofluorescence assay (IFA) using amastigotes present in cryostat sections from skeletal muscle of acutely infected mice (Cossio et al. 1984). Samples giving an absorbance higher than 0.2 at 490 nm and titers greater or equal to 1/15 were considered positive for ELISA and IFA respectively.

**Electrocardiographic studies** - The standard readings were registered by a Fukuda Century (Japan) electrocardiograph set to a velocity of 50 mm/sec with an amplitude of 1 mv. The uni, bipolar and precordial derivations were used (Milei et al. 1979). In all monkeys, before sacrifice, an ajmaline test was done to detect subclinical disturbances in the atrioventricular conduction (Chiale et al. 1982).

**Histopathological studies** - The infected and control monkeys were sacrificed at different times of the infection. They were anesthetized with ketamine (Ketalar, Parke Davis) and sacrificed by means of a total blood extraction by cateterism of the inferior cava vein. The tissue samples of complete autopsies were processed according to standard techniques, embedded in paraffin and stained with hematoxilin & eosin and Masson's trichrome. The lesions were classified as previously described (Ruiz et al. 1986); briefly, in myocardium they were nominated according to its intensity as slight (LCM), moderate (MCM) and severe chronic (SMC) myocarditis.

**RESULTS**

The parasitological pattern during the acute phase is shown in Fig. 1. During this period,

TABLE I

Schedule of experimental infection. No. monkeys, no. and timing of inoculation and reinoculations with CA1 and Tulahuén *Trypanosoma cruzi* strains

No. of animals	0 dpi	300 dpi	518 dpi	565 dpi	775 dpi
9	CA1,MT 4 x 10 <sup>4</sup>				
1	CA1,MT 4 x 10 <sup>4</sup>	CA1,MT 7,5 x 10 <sup>4</sup>			
2	CA1,MT 4 x 10 <sup>4</sup>	CA1,MT 7,5 x 10 <sup>4</sup>		CA1,MT 1,5 x 10 <sup>5</sup>	
3	CA1,MT 4 x 10 <sup>4</sup>			CA1,MT 1,5 x 10 <sup>5</sup>	CA1,BT 1 x 10 <sup>6</sup>
1	CA1,MT 4 x 10 <sup>4</sup>	CA1,MT 7,5 x 10 <sup>4</sup>		CA1,MT 1,5 x 10 <sup>5</sup>	CA1,BT 1 x 10 <sup>6</sup>
2	CA1,MT 4 x 10 <sup>4</sup>		Tulahuén,BT 2,5 x 10 <sup>3</sup>		
2	CA1,MT 4 x 10 <sup>4</sup>	CA1,MT 7,5 x 10 <sup>4</sup>	Tulahuén,BT 2,5 x 10 <sup>3</sup>		

dpi: days post infection; MT: metacyclic tripomastigotes; BT: blood trypomastigotes

subpatent parasitemia was evidenced in all infected monkeys up to day 30 pi, in two monkeys at day 60 and by day 90, parasites were not detected; patent parasitemia was observed in only one monkey at 30 days pi. After this period, during the chronic phase, parasitemia levels remained undetectable, becoming sporadically positive by xenodiagnosis, in spite of re-inoculations with  $7.5 \times 10^4$  MT of CA1 strain or  $1.5 \times 10^5$  MT of the same strain at 300 days and 567 days respectively (not shown). Parasites could not be demonstrated in the blood of monkeys even through hemoculture, artificial xenodiagnosis or inoculations in nude mice performed at 430 and 470 days pi (not shown).

Re-inoculation of four monkeys with  $2.5 \times 10^3$  BT of highly virulent Tulahuén strain at 518 days pi induced again subpatent parasitemia, up to days 699 and 776 (Fig. 2). Only high inocula ( $1 \times 10^6$  BT) of CA1 strain at day 775 induced patent parasitemia more persistently at days 788 and 801 in other four re-inoculated monkeys; after this time subpatent parasitemia was detected up to day 993 pi in two sacrificed monkeys and it became undetectable until the end of the experiment at 1200 days pi in the last sacrificed monkey (Fig. 3).

Serological conversion was observed in all infected monkeys. Titers were low, regardless of the methods used to detect *T. cruzi* specific antibodies. A peak of anti-*T. cruzi* antibodies was detected during the acute phase between 20-90 days pi in the 20 infected monkeys, which persisted, though with lower levels up to 250 days pi. Re-inoculation with  $7.5 \times 10^4$  MT of CA1 strain of six monkeys at 300 days pi did not induce differences in the antibody titers with respect to the non re-

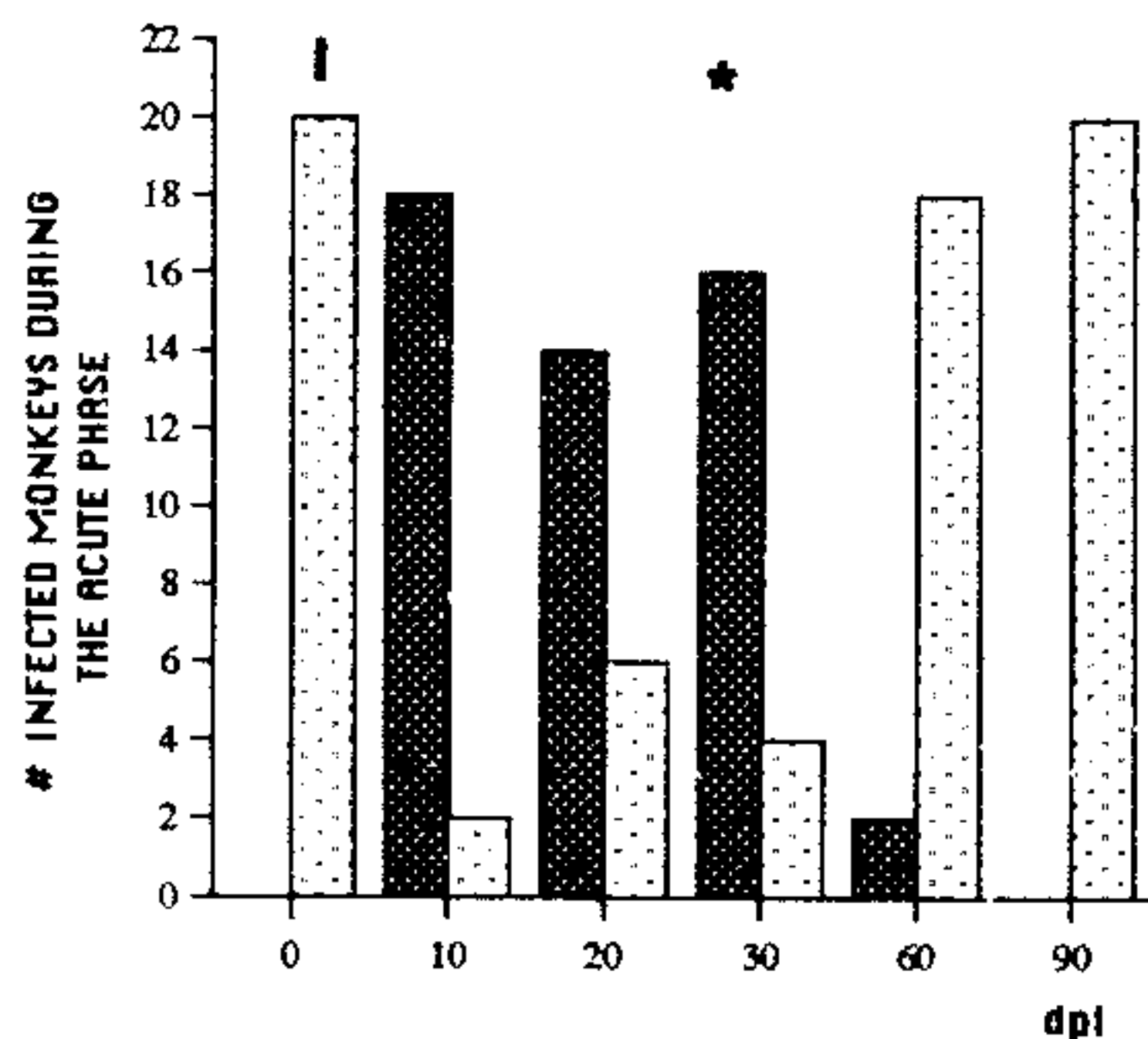


Fig. 1: ■ subpatent parasitemia detected by xenodiagnosis in the acute phase. □ No blood parasites. \* Isolated patent parasitemia.

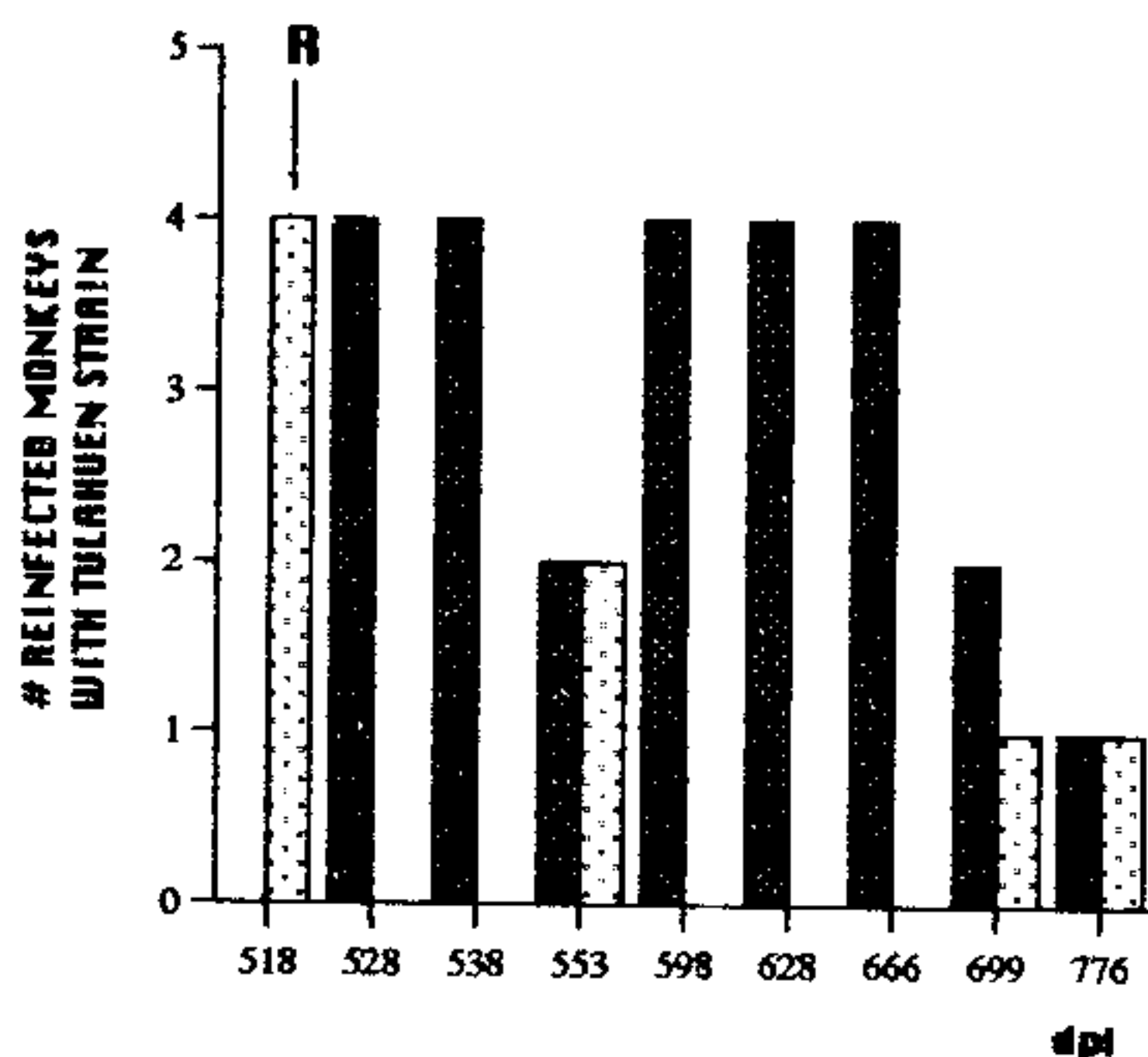


Fig. 2: re-inoculation (R) with  $2.5 \times 10^3$  blood forms of virulent Tulahuén *Trypanosoma cruzi* strain at day 518 pi. ■ Subpatent parasitemia (xenodiagnosis). □ No blood parasites.

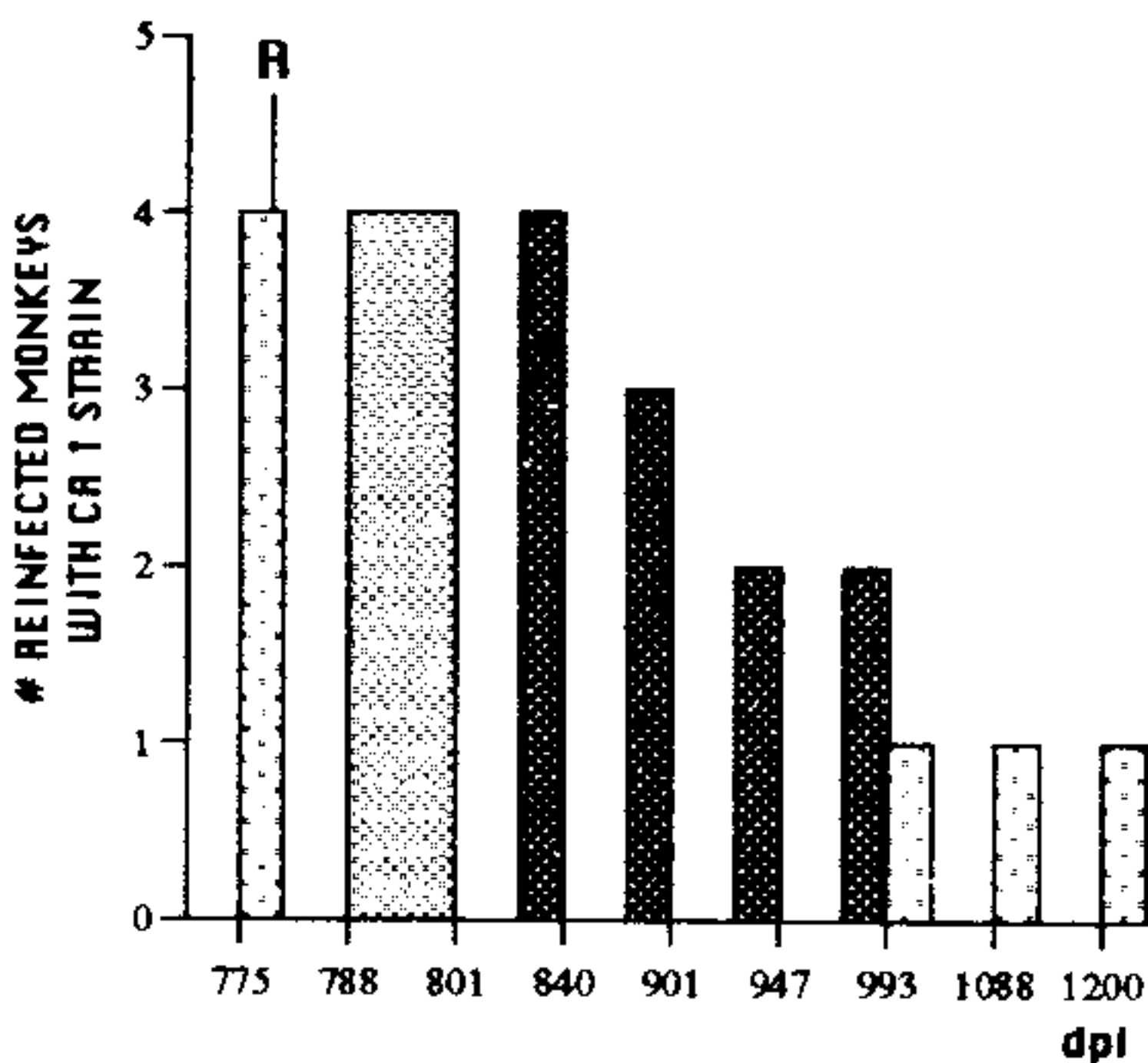


Fig. 3: re-inoculation (R) with  $1 \times 10^6$  blood forms of CA1 strain at day 775 pi. ■ Patent parasitemia (Strout method). ■ Subpatent parasitemia (xenodiagnosis). □ No blood parasites.

inoculated infected controls. IFA showed very low titers at 470 days pi and ELISA was negative in all infected monkeys in the same period (Fig. 4A, B). This low or negative serological status was not modified by a new re-inoculation with  $1.5 \times 10^5$  MT of CA1 strain in six monkeys at 567 days pi; however, the highest and most persistent antibody levels were observed when four monkeys were re-inoculated with  $2.5 \times 10^3$  BT of Tulahuén strain, at 518 days pi (Fig. 4C, D). In addition, a new narrow peak of specific antibodies, detected by both techniques, was induced in four monkeys by a third re-inoculation with  $1 \times 10^6$  BT of CA1 strain at 775 days pi (Fig. 4E, F). No clinical, electrocardio-

graphic and ajmaline test differences between both infected and control monkeys were found.

No significant differences were observed in the weight of the organs of all sacrificed monkeys (not shown). The histopathological studies at different times always showed LCM and/or MCM, lesions characterized by focal or multifocal mononuclear cell infiltrates and/or isolated sequelar fibrosis (Fig. 5). In addition, neither amastigote nests nor active inflammation and fibrogenic processes, characteristic of human chagasic acute and chronic myocarditis respectively, were observed.

Table II shows that subpatent parasitemias did not correlate with the presence of histopathological lesions at sacrifice. A total of eight monkeys had cardiac involvement and in only two of them, parasites were detected by xenodiagnosis; two additional monkeys showed subpatent parasitemias




Fig. 5: chronic myocarditis in *Cebus* monkey. Mononuclear inflammatory cells with focal distribution in heart. H&E 160X.

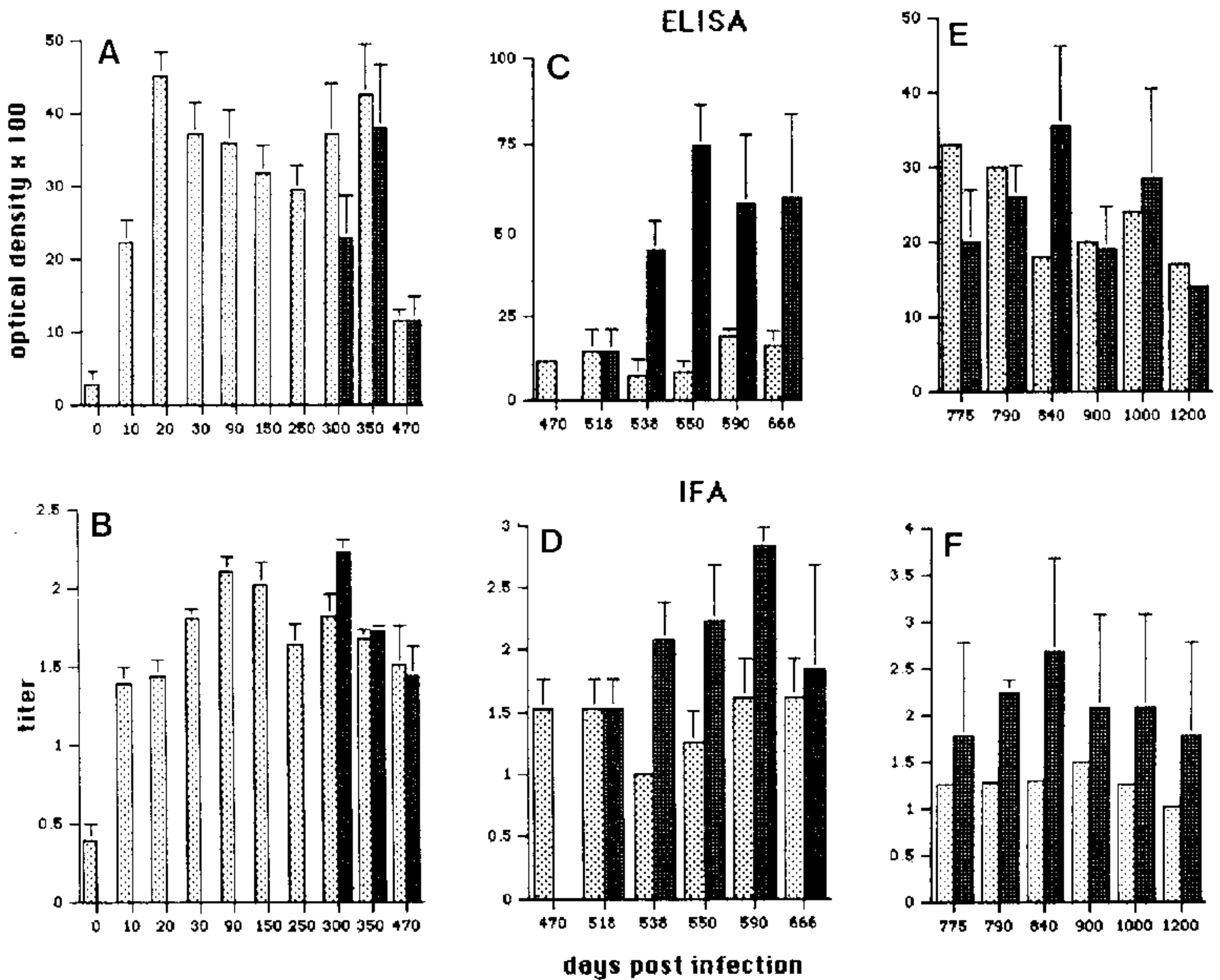


Fig. 4: anti-*Trypanosoma cruzi* antibody profile during the experimental period, detected by ELISA (upper panel) and immunofluorescence assay (lower panel). A and B: antibody levels after infection (I) with  $4 \times 10^4$  CA1 strain and re-inoculation (R) with  $7.5 \times 10^4$  CA1 strain at 300 days pi.  $\square$  Infected monkeys (n=20 at d 0).  $\blacksquare$  Re-inoculated monkeys (n=6). C and D: antibody level after R with  $2.5 \times 10^3$  parasites of Tulahuén strain at 518 days pi.  $\blacksquare$  Re-inoculated monkeys (n=4).  $\square$  Non re-inoculated infected monkeys (n=6). E and F: R with  $1 \times 10^6$  CA1 strain at 775 days pi.  $\blacksquare$  Re-inoculated monkeys (n=4).  $\square$  Non re-inoculated infected monkey (n=1). ELISA + (optical density x 100): > 20. IFA +: > 15 (15 = 1.18 log). Each point represents the logs of the reciprocal end point dilution.

TABLE II  
Relationship between monkeys, xenodiagnosis and histopathological lesions at sacrifice

Days pi	Monkeys (control monkeys)	Strain (inoculations)	Xeno	Lesion
90	448	CA1 (1)	-	No
	319 (2)	CA1 (1)	-	No
	354	CA1 (1)	-	No
250	446	CA1 (1)	-	No
	398	CA1 (1)	-	No
	377 (3)	CA1 (1)	-	No
	381	CA1 (1)	-	LCM
	397	CA1 (1)	-	LCM
430	367 (1)	CA1 (1)	-	No
	450	CA1 (2)	-	No
666	470 (1)	CA1 (3)	-	No
	400	CA1 (1)/TUL (1)	+	LCM
880	521	CA1 (3)	+	No
	383 (1)	CA1 (2)/TUL (1)	-	MCM
	465	CA1 (2)/TUL (1)	-	MCM
1000	451 (2)	CA1 (3)	+	MCM
	363	CA1 (4)	+	No
1200	245	CA1 (3)	-	LCM
	480 (2)	CA1 (3)	-	No
	532	CA1 (1)/TUL (1)	-	MCM

pi: post infection; control monkeys sacrificed simultaneously with infected monkeys; LCM: light chronic myocarditis; MCM: moderate chronic myocarditis

without tissue abnormalities. Only 4/16 monkeys receiving one or more inocula of CA1 strain showed tissue lesions, three with LCM and one with MCM. In contrast, all animals (4/4) re-inoculated with Tulahuén strain evidenced cardiac lesions: 3/4 had MCM and 1/4 presented LCM. No mortality occurred. The 12 control monkeys sacrificed simultaneously with the infected animals throughout the experiment did not show lesions in the different organs studied.

#### DISCUSSION

The close phylogenetic relationship between man and non-human primates, and their potential usefulness as experimental models in studies of American trypanosomiasis have generated interest in these animal species.

The susceptibility of monkeys to *T. cruzi* was evidenced for the first time in 1911 by Carlos Chagas, when flagellated parasites were isolated from the blood of experimentally infected *Callitrix penicilata* monkeys (Chagas 1922). Some New World monkeys were found naturally infected with *T. cruzi*, being the prevalence of infection of *C. apella* and *Saimiri sciureus* higher than that of *Aotus trivirgatus* and *Alouatta caraja* (Da Rocha

et al. 1966, Travi et al. 1982). Natural infection was also evidenced in 3% of 240 *Cebus* monkeys captured in the wilderness and kept at the Universidad del Salvador indoor colony (E Segura, personal communication).

Previous studies have demonstrated that *Cebus* monkeys developed low levels of parasitemia during long-term infection with *T. cruzi* CA1 strain (Bolomo et al. 1980, Enders et al. 1982). However, higher parasitemias do occur during the acute phase of infection in New and Old World monkeys with more virulent strains of the parasite such as Tulahuén (A Sinagra, personal communication), Y, Peru, Barbosa, Brazil and RA strains (Seah et al. 1974, Marsden et al. 1976, Chaia et al. 1977, Enders et al. 1982, Lima João et al. 1986, Rosner et al. 1989). In this study, *C. apella* monkeys showed low levels of parasitemia after infection with CA1 and re-inoculation with Tulahuén strain. Exacerbation of parasitemia was only seen upon reinfection with a high dose of CA1.

As in human Chagas' disease, New and Old World monkeys develop specific anti-*T. cruzi* antibodies during acute and chronic infection with Y, San Felipe, RA (Granado et al. 1983, Rosner et al. 1989), Colombiana (Falasca et al. 1986), Peru

(Seah et al. 1974) and Brazil (Enders et al. 1982) *T. cruzi* strains. In our work, low titers of specific anti-*T. cruzi* antibodies were also demonstrated throughout infection with the CA1 strain. It is noteworthy that some monkeys became parasitologically and serologically negative after the first year pi and remained in that status in spite of re-inoculations with increasing doses of the CA1 parasite strain. Only the last re-inoculation with a high dose of CA1 or the more virulent Tulahuén strain was able to induce once more detectable parasitemia and a higher specific antibody response. Classically, in human Chagas' disease serological cure has been demonstrated only after treatment with trypanocidal drugs (Cerisola et al. 1972, Moya et al. 1985). However, spontaneous serological cure has been recently reported in humans (Zeledon et al. 1988) and the parasitological and serological findings in CA1 infected and resistant *Cebus* monkeys, that express a characteristic "self limiting" *T. cruzi* infection, would give experimental support to those sporadic findings on human cases.

*T. cruzi* acute myocarditis similar to that found in humans has been described in New (Torres & Tavares 1958) and Old World monkeys (Enders et al. 1982, Lima João et al. 1986, Bonecini-Almeida et al. 1990). Chronic myocarditis has been reported in *Cebus* monkeys (Bolomo et al. 1980, Falasca et al. 1986) and in rhesus monkeys (Miles et al. 1979, Bonecini-Almeida et al. 1990). However, the histopathological characteristics of chronic myocarditis described in *Cebus* monkeys are apparently similar to that observed in this work, and consisted mainly of focal and multifocal inflammatory cell infiltration and/or sequellar fibrosis. In our experience these characteristics look more like the "indeterminate type" of Chagas' disease (Andrade et al. 1981), clearly different to the human chronic chagasic myocarditis which features a more diffuse and progressive fibrogenic pattern of the disease. These morphological aspects resemble features reported in hearts from patients undergoing the indeterminate phase of Chagas' disease characterized by focal chronic myocarditis, fibrosis and degenerative processes (Vivarelli Curti et al. 1979). In addition, cardiac invasive and non-invasive studies have also revealed abnormal features in asymptomatic patients (Milanes et al. 1982, Carrasco Guerra et al. 1987). Neither pathological aspects nor cardiac alterations are expressed clinically and they might represent sequels of the acute phase (Andrade et al. 1985). Experimental studies suggest that the evolution of *T. cruzi* infection to the indeterminate phase in New (Bolomo et al. 1980, Granado et al. 1983 and

this work) and Old (Marsden et al. 1976, Miles et al. 1979, Bonecini-Almeida et al. 1990) World monkeys might mimic the indeterminate phase of Chagas' disease seen in a large percentage of infected humans. Nevertheless, a morphological pattern similar to the human cardiomyopathy has been described in *Cebus* monkeys infected with virulent *T. cruzi* strains (Rosner et al. 1989).

The "self limited" infection seen in CA1 infected *Cebus* monkeys as described in different reports (Bolomo et al. 1980, Falasca et al. 1989) and in this work, is not exclusive of this host-parasite pair, since it has also been observed in Y and Tulahuén *T. cruzi* strains-infected *Cebus* monkeys (Chaia et al. 1977, Sinagra et al. personal communication) or in Peruvian and Colombian *T. cruzi* strain-infected rhesus monkeys (Marsden et al. 1976, Bonecini-Almeida et al. 1990). On the contrary, a typical acute phase with parasitological, serological, clinical and morphological changes was described in rhesus monkeys (Enders et al. 1982, Lima João et al. 1986) but not in *Cebus* monkeys although they had been also infected with virulent strains such as Tulahuén (Falasca et al. 1986) Y or RA (Granado et al. 1983, Rosner et al. 1989). Nevertheless, acute histopathological changes were exceptionally described in *Cebus* monkeys after frequent re-inoculations with very large number of parasites during the acute phase (Torres & Tavares 1958).

In this work, the primary immune response elicited in *Cebus* monkeys by the primoinfection with CA1 strain was able to modulate and inhibit the parasitic, serologic and pathologic findings of *T. cruzi* homologous re-inoculations. However the resistance of *Cebus* monkeys to re-inoculations can be broken by re-inoculations performed with the virulent Tulahuén parasites, or very high inocula of the CA1 strain, which modify the parasitemia, antibody titers, and pathological aspects of the chronic infection. Changes in the course of the *T. cruzi* chronic infection, evidence by an increase in parasitemia levels and in the titer of antibodies were also described after re-inoculation with the Tulahuén strain in these monkeys (Falasca et al. 1986). In other animal models such as mice several reports suggest that re-inoculations do not induce changes in the evolution of Chagas' disease. In a recent study, inoculated and re-inoculated mice with high doses of *T. cruzi* parasites, developed steady and highly protective and conventional antibodies throughout the infection, regardless of the parasite strains used and successive re-inoculations (Pereira & Kretzli 1990). However, re-inoculations with low doses of Tulahuén parasites were able to provoke reinfections and

twist the course of murine chronic infection in terms of mortality, parasitemia and severity of lesions (Cabeza Meckert & Laguens 1981). In humans, in a longitudinal study performed in São Felipe, Brazil, evidence was presented that people living in triatomine infested houses and therefore potentially exposed to repeated bites, presented a more frequent, more severe evolution and higher mortality due to Chagas cardiomyopathy, when compared with those living in non-infested houses (Macedo 1976). Experimentally, our results and those mentioned previously demonstrate that re-inoculations change the evolution of chronic *T. cruzi* infection depending on the dose of parasites, type of *T. cruzi* strain and the animal models used. These studies would give support to the hypothesis that people living in endemic areas may not always be protected against reinfection and their pathological state could worsen after re-inoculations, as it was observed in one patient (V Macedo, personal communication).

Electrocardiography has been used as a mean to evaluate myocardial involvement during acute and chronic chagasic myocarditis in monkeys. Electrocardiographic abnormalities suggesting myocarditis have been described in prepuberal (Bolomo et al. 1980) and adult *C. apella* (Falasca et al. 1986, Rosner et al. 1989) *Saimiri sciureus* (Pung et al. 1988), *Macaca mulatta* (Miles et al. 1979) and other rhesus monkeys (Lima João et al. 1986). However, a lack of relationship is observed between these abnormalities and heart histopathological lesions in those reports, although they were not directed to specifically analyze the heart conduction system. In our work, infected or reinfected monkeys did not develop electrocardiographic changes during the three years of the duration of this study. Therefore, at present, the sensitivity of the electrocardiogram in monkeys remains to be determined through further experiments involving careful morphologic studies of the heart and an adequate number of animals to give significance to the results.

These studies indicate that New and Old World monkeys are susceptible to *T. cruzi* infection since they are able to develop different characteristics of acute *T. cruzi* infection. However, monkeys recover from acute infection and enter into an indeterminate phase with scarce morphological changes.

Therefore, monkeys are a good model for chemotherapy and immunoprophylactic methods in the acute phase and undetermined form of Chagas' disease, but systematic, controlled and matched studies are necessary to confirm the value of this important model system for the chronic chagasic cardiomyopathy.

## ACKNOWLEDGEMENTS

To Dr Mirta Carlomagno for her critical review of the manuscript, Dr C del Prado for the photographs, and Mrs Esther San Esteban, Miss Luisa Fernández and Miss Celia Vila for their technical assistance.

## REFERENCES

- Abramo Orrego L, Lansetti JC, Bozzini JP, Wynne de Martini G 1980. Hemocultivo como método de diagnóstico de la Enfermedad de Chagas. *Medicina (B Aires)* 40 (Supl 1): 56-62.
- Andrade ZA 1985. A patologia da doença de Chagas no homem. *Ann Soc Belg Med Trop* 65 (Suppl): 15-22.
- Andrade ZA, Andrade SG, Sadigursky M, Maguire JH 1981. Experimental Chagas' disease in dogs. A pathological and ECG study of the chronic indeterminate phase of the infection. *Arch Pathol Lab Med* 105: 460-464.
- Bijovsky T, Elizari MV, Muller LA, Katzin VJ, González Cappa SM 1983. Chronic infection in mice with *Trypanosoma cruzi*. *Rev Inst Med Trop S Paulo* 25: 207-214.
- Bolomo N, Milei J, Cossio P, Segura EL, Laguens RP, Fernández L, Arana RM 1980. Enfermedad de Chagas experimental en un primate sudamericano (*Cebus* sp.). *Medicina (B Aires)* 40: 667-672.
- Bonecini-Almeida MG, Pessoa MHR, Pirmez C, Laranja F, Galvão-Castro B 1990. *Trypanosoma cruzi*: Experimental Chagas' disease in rhesus monkey. I. Clinical, parasitological, haemathological and anatomopathological studies in the acute and indeterminate phases. *Mem Inst Oswaldo Cruz* 85: 163-171.
- Cabeza Meckert P, Laguens RP 1981. Chronic Chagas' disease in the mouse. III. Absence of concomitant immunity after repeated infections. *Medicina (B Aires)* 41: 543-548.
- Carrasco Guerra HA, Palacios Pru E, Dagert de Scorza C, Molina C, Inglessis G, Mendoza RV 1987. Clinical, histochemical and ultrastructural correlation in septal endomyocardial biopsies from chronic chagasic patients: detection of early myocardial damage. *Am Heart J* 113: 716-724.
- Cerisola JA, Lugones H, Rabinovich L 1972. *Tratamiento de la Enfermedad de Chagas*, p. 31-47. 6° Premio Rizzuto. Ed Fundación Rizzuto. Buenos Aires, Argentina.
- Cerisola JA, Rhowedder R, Segura EL, Del Prado CE, Winni de Martini G 1974. *El xenodiagnóstico: normalización-utilidad*, p.50-60. Publicación del Ministerio de Bienestar Social Buenos Aires, Argentina.
- Chagas C 1922. Descoberta do *Trypanosoma cruzi* e verificação da Tripanosomíase Americana. *Mem Inst Oswaldo Cruz* 15: 67-176.
- Chaia G, Barbosa de Abreu I, Chiari L, Moura Araújo S 1977. Infecção experimental de macacos *Cebus apella* sp. pelo *Trypanosoma cruzi* (cepa Y). *Rev Inst Med Trop S Paulo* 2: 81-85.
- Chiale PA, Przybylski J, Laino RA, Halpern MS, Sanchez A, Gabrieli R, Elizari M, Rosebaum M 1982. Electrocardiographic changes evoked by ajmaline in chronic Chagas' disease without manifest myocarditis. *Am J Cardiol* 49: 14-20.

- Cossio P, Bustuoabad O, Paterno E, Iotti R, Casanova M, Podestá MR, Bolomo N, Arana R, Pascualini C 1984. Experimental myocarditis induced in Swiss mice by homologous heart immunization resembles chronic experimental Chagas' heart disease. *CI Immunol Immunopathol* 33: 165-175.
- Da Rocha Carvalheiro, Pereira Barreto M 1966. Estudos sobre reservatórios e vetores silvestres do *T. cruzi*: Infecção natural do macaco *Cebus apella* versus Elliot, 1910 por tripanossomo semelhante ao *T. cruzi*. *Rev Brasil Biol* 2: 101-114.
- Enders B, Weinmann E, Nagle CA, Hein B, Zwisler O 1982. Experimental Chagas' disease in primate *Macaca fascicularis* and *Cebus apella* with special reference to preclinic trials and the evaluation of a living non-replicating *T. cruzi* vaccine. *Behring Inst Mitt* 71: 132-156.
- Falasca A, Grana D, Buccolo J, Gili M, Merlo A, Zoppi J, Mareso E 1986. Susceptibility of the *Cebus apella* monkeys to different strains of *T. cruzi* after single or repeated inoculations. *PAHO Bull* 20: 117-137.
- González Cappa SM, Chiale P, Del Prado CE, Katzin AM, Winni de Martini G, Isola ED de, Abramo Orrego L, Segura EL 1980. Aislamiento de una cepa de *Trypanosoma cruzi* de un paciente con miocardiopatía chagásica y su caracterización biológica. *Medicina (B Aires)*, 40 (Supl 1): 63-68.
- Granado N, Navarro Rassi MR, Nogarato SL, Carvalhal S, Almeida Eros A, Chaia G 1983. Infecção experimental de macacos *Cebus apella* sp. pelo *Trypanosoma cruzi*. *Rev Inst Med Trop S Paulo* 6: 283-287.
- Lima João AC, Szarfman A, Lima S, Adams RJ, Russel R, Cheever A, Trischman T, Weiss J 1986. Absence of left ventricular dysfunction during acute chagasic myocarditis in the rhesus monkey. *Circulation* 1: 172-179.
- Macedo VO 1976. Influencia de la exposición a la reinfección en la evolución de la enfermedad de Chagas (Estudio longitudinal de cinco años). *Rev Pat Trop* 5: 33-39.
- Marsden PD, Seah SKK, Drapper CC, Pettit IE, Miles MA, Voller A 1976. Experimental *Trypanosoma cruzi* infections in rhesus monkeys. II. The early chronic phase. *Trans R Soc Trop Med Hyg* 3: 247-251.
- Milanes JC, Carrasco HA, Bellera J, Torres A, Fuenmayor A 1982. High frequency electrocardiography in the early diagnosis of myocardial damage in patients with Chagas' disease. *Arch Inst Cardio Mex* 52: 477-482.
- Milei J, Vásquez A, Fortunato MR, Bolomo NJ 1979. El electrocardiograma normal en el *Cebus* sp. *Medicina (B Aires)* 39: 208-212.
- Miles MA, Marsden PD, Pettit LE, Drapper CC, Watson S, Seah SKK 1979. Experimental *Trypanosoma cruzi* infections in rhesus monkeys. III. Electrocardiographic and histopathological findings. *Trans R Soc Trop Med Hyg* 5: 528-532.
- Moya PR, Paolasso R, Blanco S, Lapasset M, Sanmartino C, Basso B, Moretti E, Cura D 1985. Tratamiento de la Enfermedad de Chagas con Nifurtimox durante los primeros meses de vida. *Medicina (B Aires)* 45: 553-558.
- Pereira MES, Krettli AU 1990. The effect of re-inoculations with trypomastigotes in the level of protective antibodies in mice chronically infected with *T. cruzi*. *Brazilian J Med Biol Res* 23: 283-292.
- Pizzi T, Prager R 1952. Estabilización de la virulencia de una cepa de *Trypanosoma cruzi* por pasaje seriado en ratones de constitución genética uniforme: análisis cuantitativo del curso de la infección. *Biológica* 16-17: 3-12.
- Pung OJ, Hulsevo LH, Kuhn R 1988. Experimental Chagas' disease (*Trypanosoma cruzi*) in the Brazilian squirrel monkey (*Saimiri sciureus*): hematology, cardiology, cellular and humoral immune responses. *Int J Parasitol* 1: 115-120.
- Rosner JM, Bellasai J, Schinini A, Rovira T, Arias AR de, Ferro EA, Ferreira E, Velásquez G, Monzón MI, Maldonado M, Galeano R, Fresco MA 1989. Cardiomyopathy in *Cebus apella* monkeys experimentally infected with *Trypanosoma cruzi*. *Trop Med Parasitol* 40: 24-31.
- Ruiz AM, Esteva M, Riarte A, Subias E, Segura EL 1986. Immunoprotection of mice against *Trypanosoma cruzi* with a lyophilized flagellar fraction plus adjuvant. *Immunol Letters* 12: 1-4.
- Ruiz AM, Esteva M, Subias E, Moreno M, Rosenstein de Campanini A, Velazquez E, Segura EL 1990. Monoclonal antibodies against the flagellar fraction of epimastigotes of *Trypanosoma cruzi*: Immunoprotection against metacyclic tripomastigotes obtained by immunization of mice with an affinity purified antigens. *Mol Bioch Parasitol* 39: 117-126.
- Sánchez DO, González Cappa SM 1983. Neutralizing antibodies in *Trypanosoma cruzi* infection. *Medicina (B Aires)* 43: 41-46.
- Seah KK, Marsden PD, Voller A, Pettit IE 1974. Experimental *Trypanosoma cruzi* infection in rhesus monkeys. II. The acute phase. *Trans R Soc Trop Med Hyg* 3: 247-251.
- Strout RG 1962. A method for concentrating hemoflagellates. *J Parasitol* 48: 100.
- Torres MC, Tavares BM 1958. Miocardite no macaco *Cebus* após inoculações repetidas com *Schizotrypanum cruzi*. *Mem Inst Oswaldo Cruz* 56: 85-119.
- Travi B, Ruiz AM, Colillas OJ, Segura EL 1982. Tripanosomiasis en monos neotropicales. *Medicina (B Aires)* 42: 55-60.
- Vivarelli Curti HJ, Ribeiro Sánchez PC, Kamebley Bittencourt LA, Carvalhal S 1979. Revisão da classificação anatomoclínica da doença de Chagas. *Arq Bras Cardiol* 33: 277-283.
- Voller A, Drapper CC, Bidwell D, Barlett A 1975. Microplate ELISA for Chagas' Disease. *Lancet* 1: 426-429.
- WHO 1960. Chagas' Disease: report of a study group. Serie 202. WHO, Geneva.
- WHO 1989. Tropical Diseases. Progress in International Research, 1987-1988. Ninth Programme Report. WHO, Geneva.
- Zeledon R, Dias JC, Britta Zalazar A, de Rezende JM, Vargas L, Urbina A 1988. Does a spontaneous cure for Chagas' disease exist? *Rev Soc Bras Med Trop* 21: 15-20.